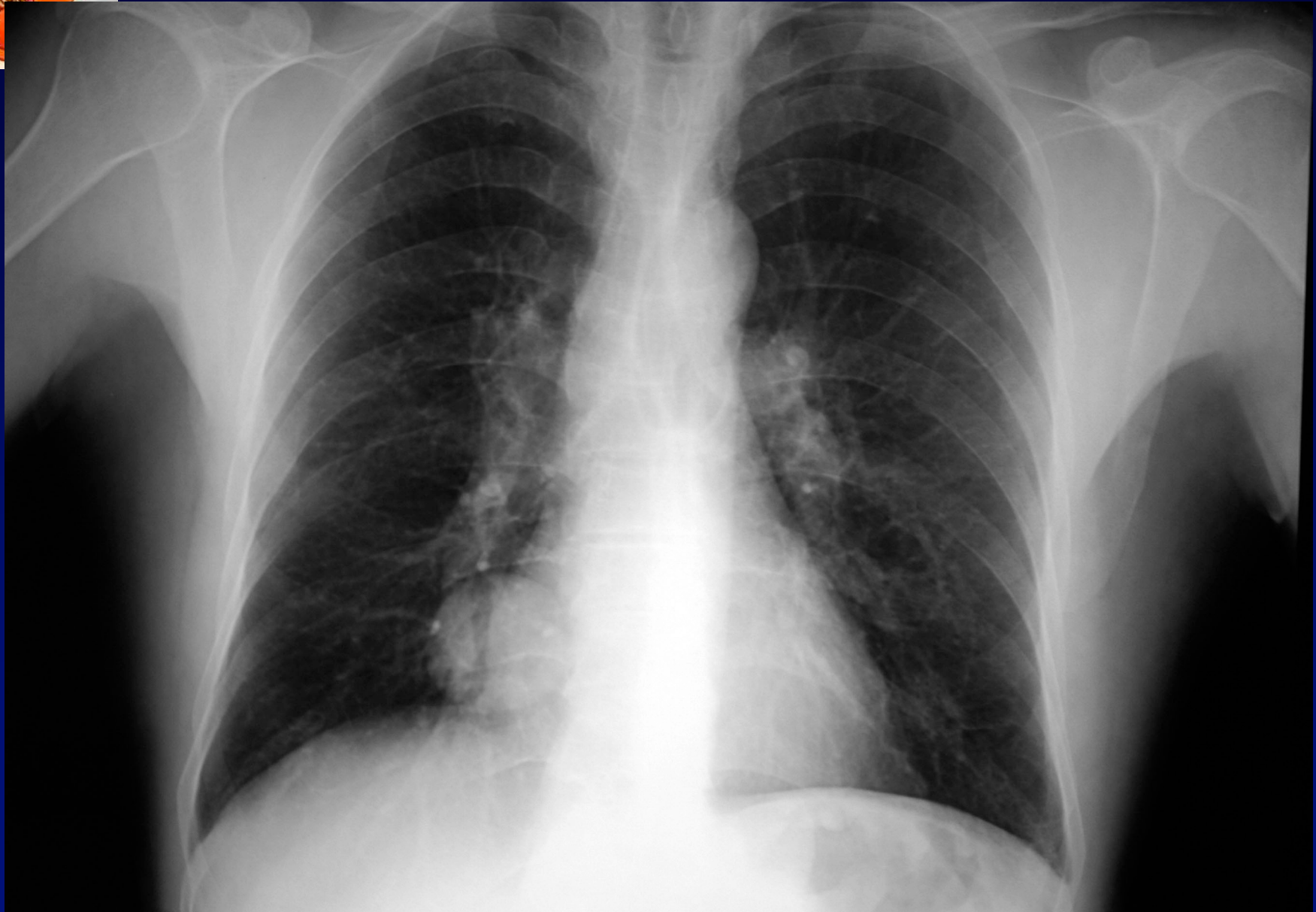
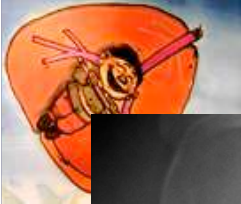
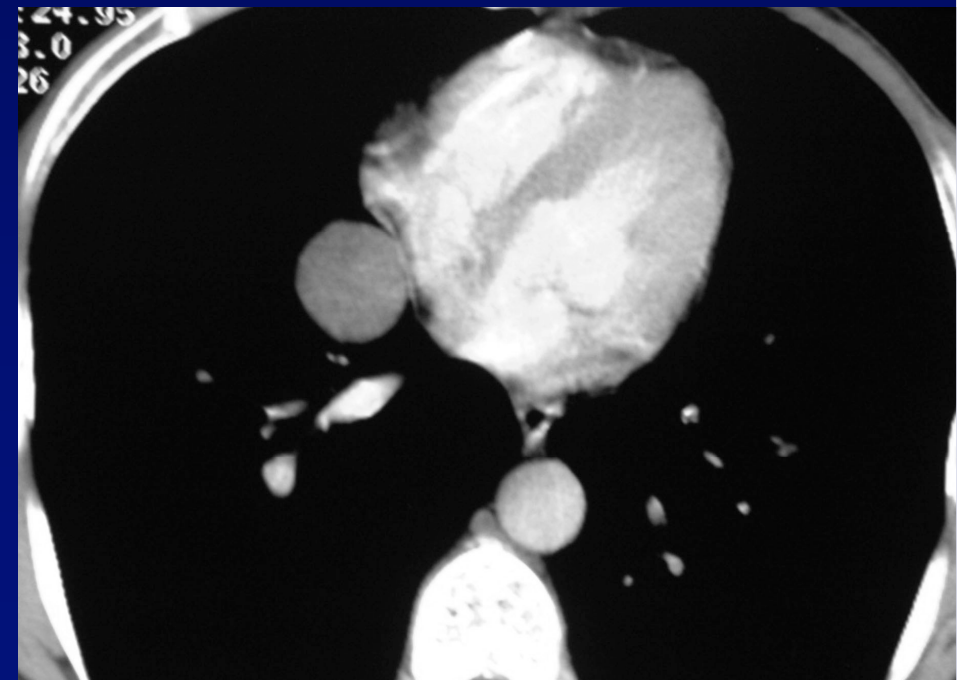
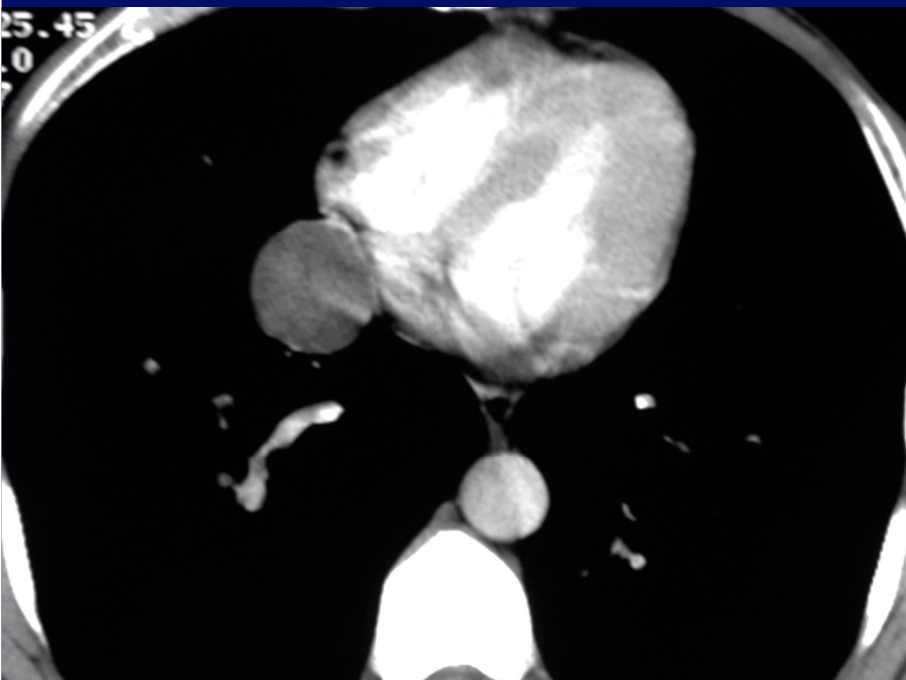
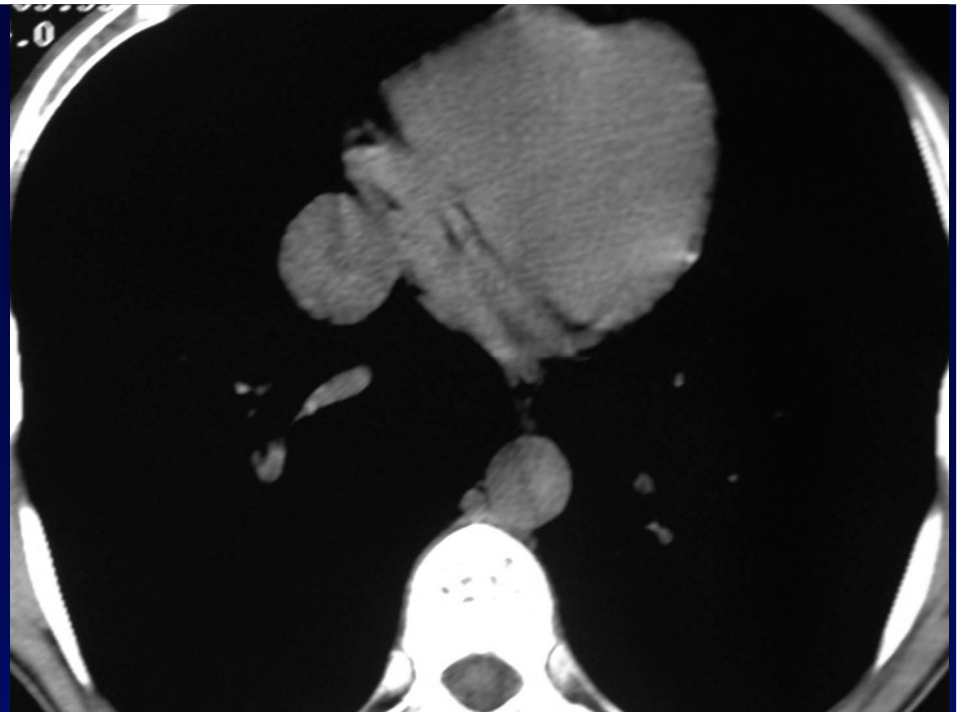
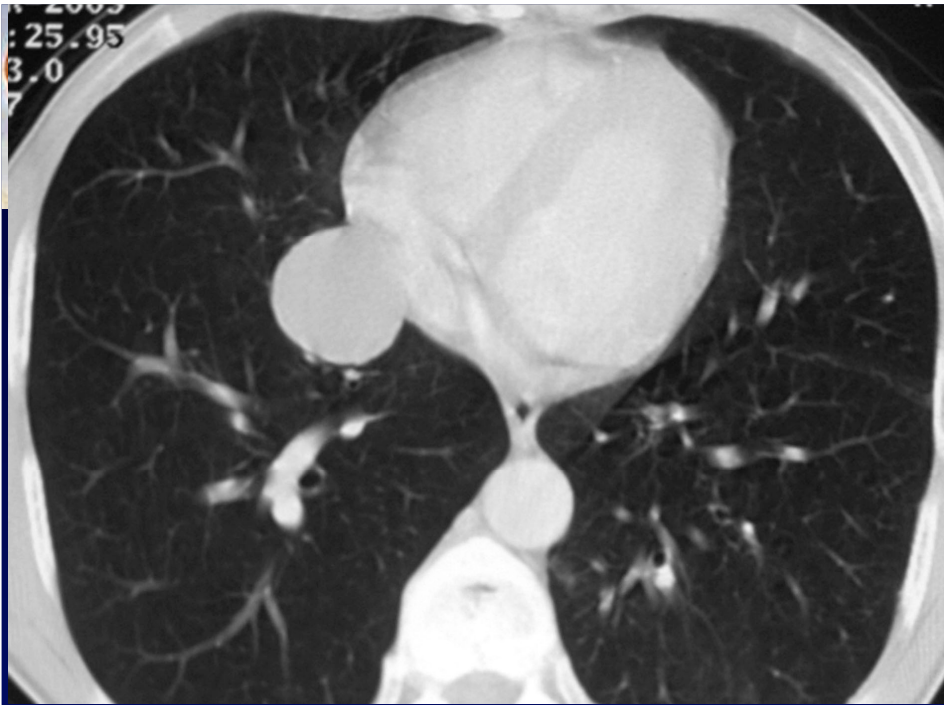


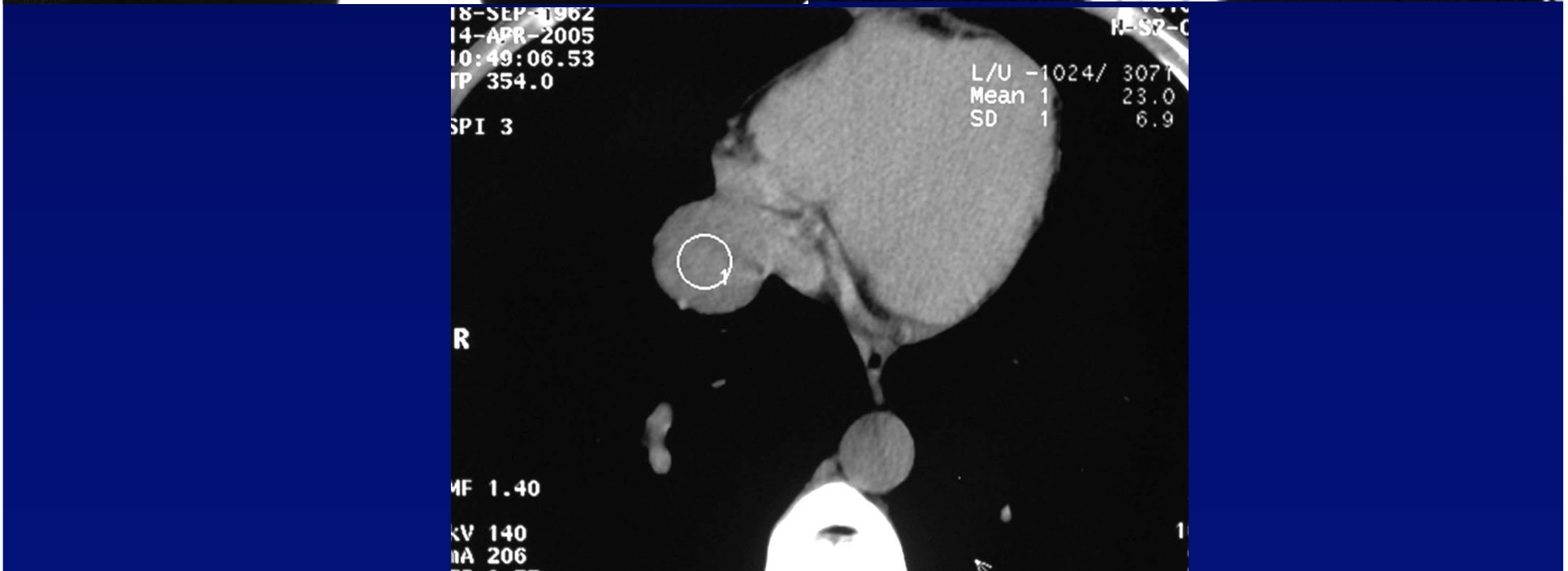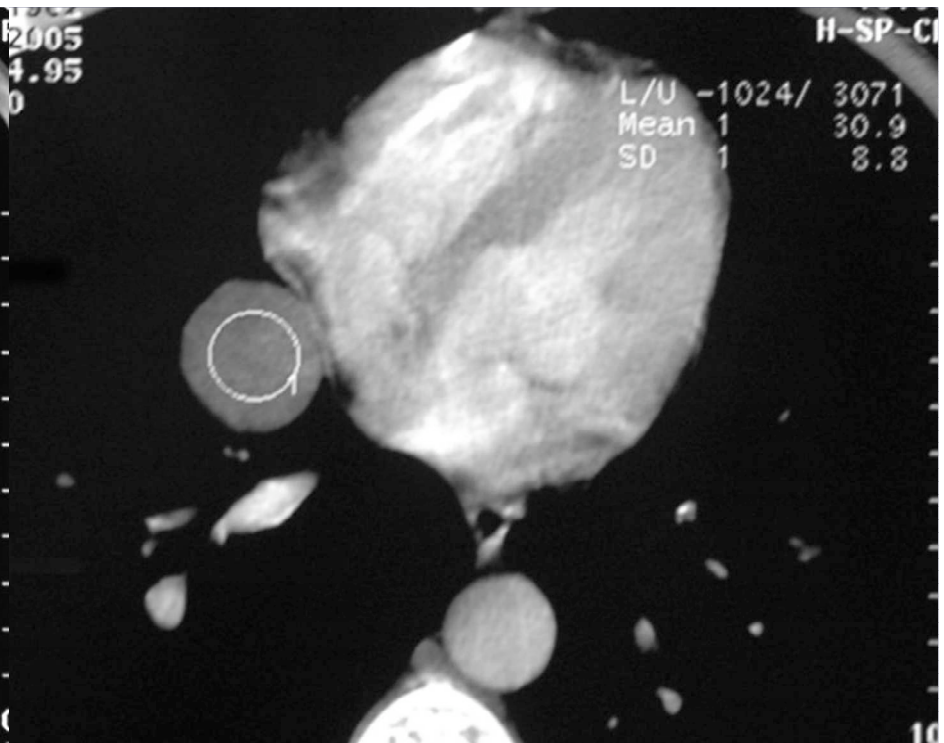
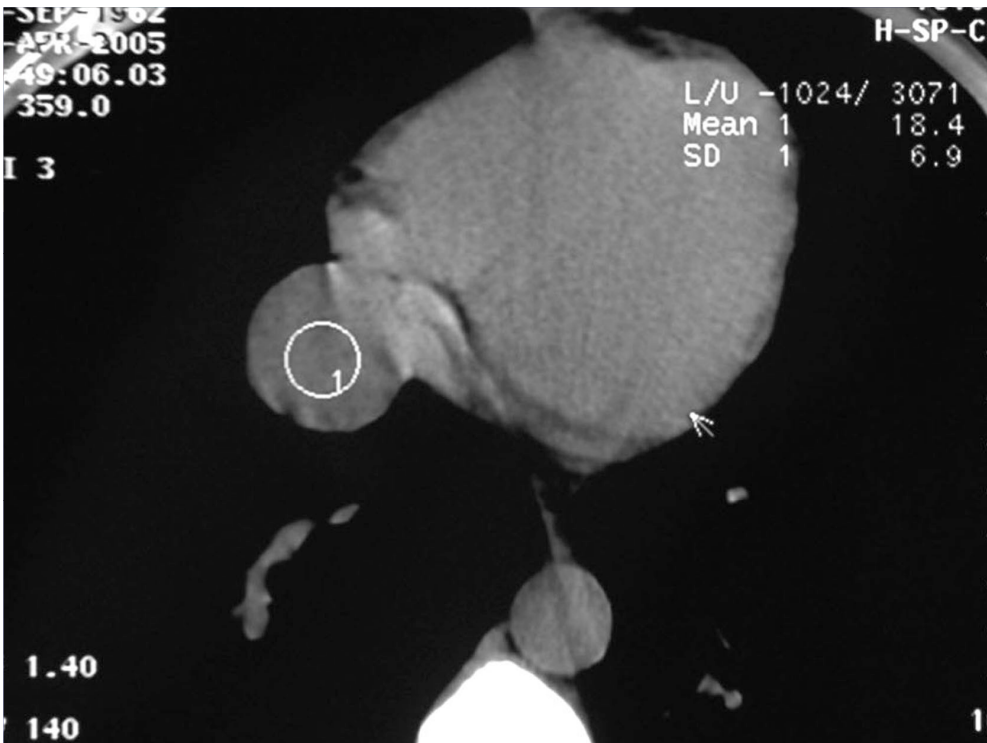**MP. DEBRAY**

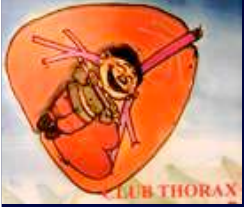**Homme de 34 ans**

**Radiographie thoracique systématique**









**Diagnostic ?**



# Diagnostic

## Hamartochondrome